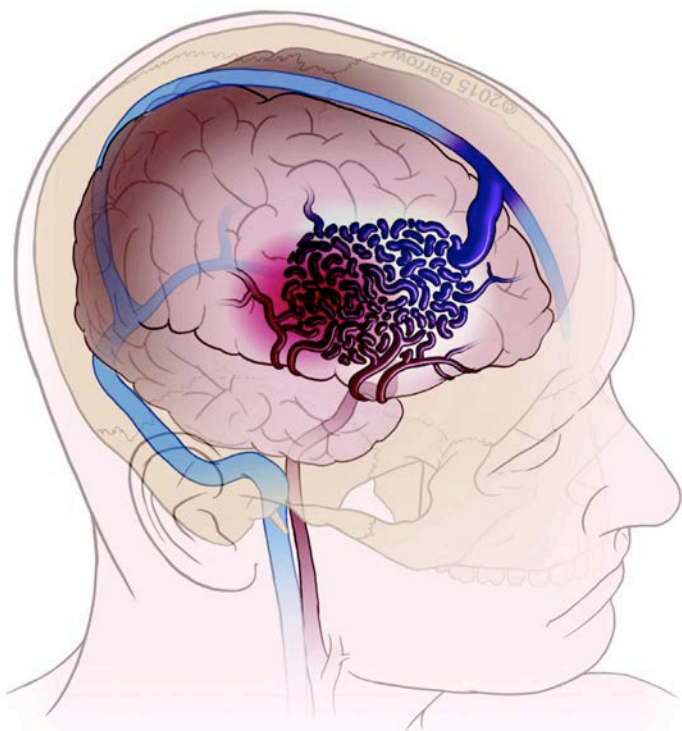


Brain Arteriovenous Malformations

What You Should Know About
the Treatment Options



©All content copyright SNIS.

What is a Brain Arteriovenous Malformation?

A brain arteriovenous malformation (AVM) is an abnormal tangle of blood vessels in the brain (Figure 1). AVMs can cause bleeding in the brain, seizures, and other neurologic problems. They occur in fewer than 1% of the population. Most patients are born with their AVMs but in some cases AVMs can form later in life. The most common age for brain AVMs to be diagnosed is in the 30s to 40s, but they can be diagnosed in children as well as older adults. Men and women are equally likely to have an AVM.

©All content copyright SNIS.

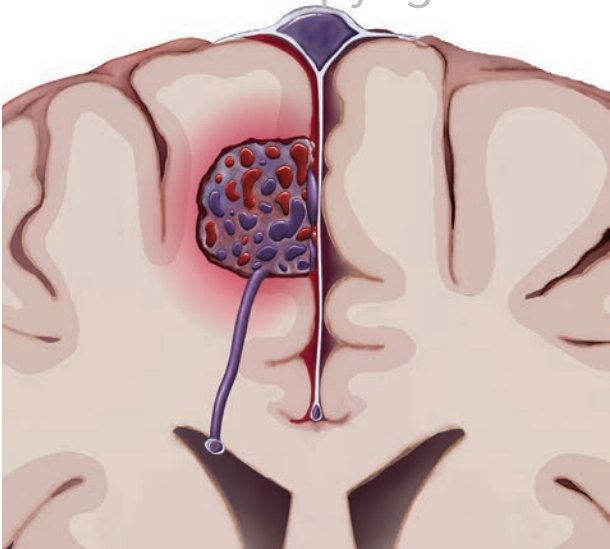


Figure 1. Schematic showing an AVM in the right cerebral hemisphere

How are AVMs Discovered?

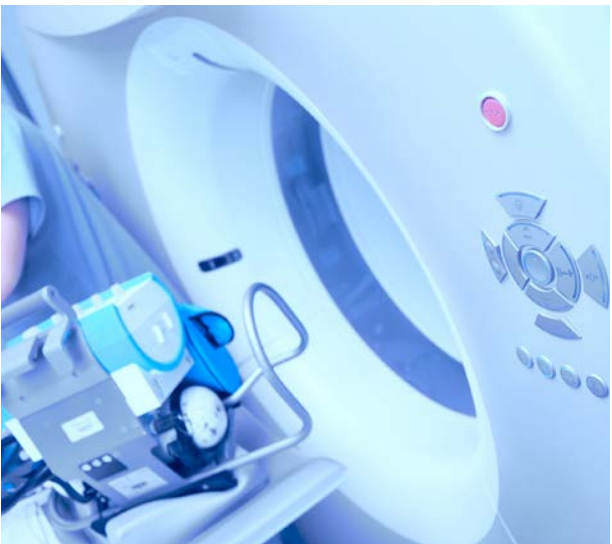Unruptured AVMs often cause no symptoms and hence are often discovered accidentally after brain imaging for other reasons. The most common first symptom caused by an AVM is bleeding in the brain. Patients whose AVMs bleed usually experience the sudden onset of a severe headache. In addition, they may also experience weakness, nausea, vomiting, neck stiffness

or sound & light sensitivity. In severe cases patients may progress to coma. AVM bleeding is associated with a 10-20% chance of death and a 10-30% chance of disability. Less commonly, the first symptom of an AVM is a seizure. The average age of patients with seizure is 25 years. Even less commonly, the first symptom of an AVM may be weakness or other focal neurologic symptoms. Persisting headaches are common in patients with AVMs, found in 5-15% of patients even before their AVM is detected. However, the large majority of people with chronic headaches in general do not have an AVM. The best available data suggests that AVMs have a 1-3% per year risk of bleeding once discovered.

© All content copyright SNIS.

How are Arteriovenous Malformations Diagnosed?

Brain AVMs can be diagnosed in different ways. Diagnosis of an AVM that has caused bleeding is typically made on Computerized Tomography (CT), which uses X-rays to view internal structures of your body, in this case, your brain. In patients where the AVM has not caused bleeding, often Magnetic Resonance Imaging (MRI) is performed, which uses magnetic and radio waves to create high resolution images of the brain tissue and surrounding structures.



To determine the exact location, size and anatomy of an AVM, the blood vessels in the brain are imaged in a test called “angiography.” Angiography can be performed non-invasively with CTA or MRA. Cerebral catheter angiography is the third option, which is an invasive test that requires a catheter to be placed into the arteries that supply the brain in order to inject contrast material (“X-ray dye”) for imaging of the blood vessels. (Figure 2) Usually the catheter is placed into the leg artery at the groin crease or at the wrist artery and gently maneuvered into the brain arteries. The procedure involves minimal discomfort and is performed with light sedation (the patient is awake). Angiography is considered the “gold-standard” for imaging an AVM. It is an invasive test, with a very small risk (<1%) of serious harm to the patient (most importantly a small risk of causing a stroke). However, catheter cerebral angiography does yield superior spatial and temporal resolution of the brain vessels.

©All content copyright SNIS.

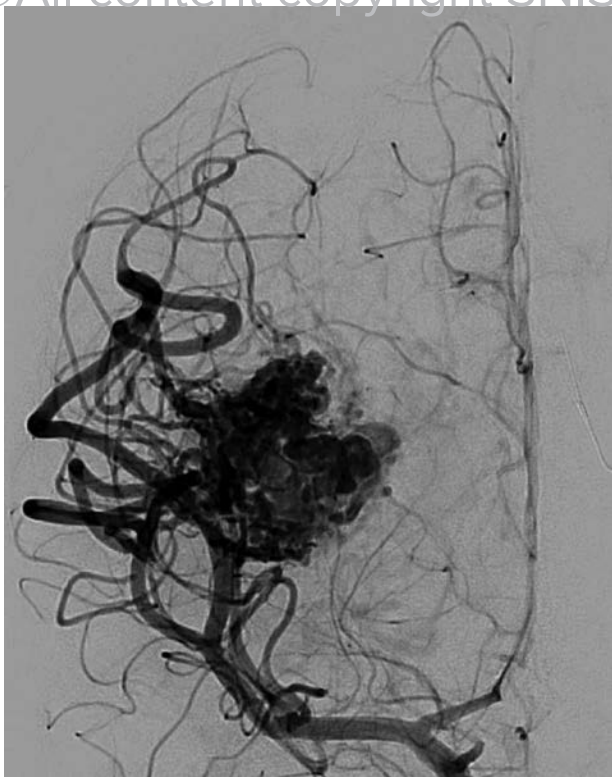


Figure 2. Cerebral angiogram showing an abnormal tangle of blood vessels characteristic of an AVM.

How are AVMs Treated?

Today there are four management options for people who have been diagnosed with a brain AVM.

Medical therapy: medications may be prescribed to manage symptom associated with the AVM (seizures for example). No effort is made to remove the AVM. This option is often chosen when attempts to directly treat the AVM may pose more risk of harm to the patient than the AVM itself.

Surgical therapy: this requires opening the skull (craniotomy) in order to remove the AVM. In order for surgery to have any benefit, the entire AVM must be removed. Surgery immediately eliminates the risk of bleeding from the AVM. However, the process of AVM removal can injure nearby brain tissue and cause harm to the patient depending on the size of the AVM and where the AVM is located. For example, removing a larger AVM in a part of the brain that performs important functions is riskier than removing a smaller AVM in a part of the brain that is “less important.” After removing the AVM, the skull bone is secured in its original position (Figure 2, 3).

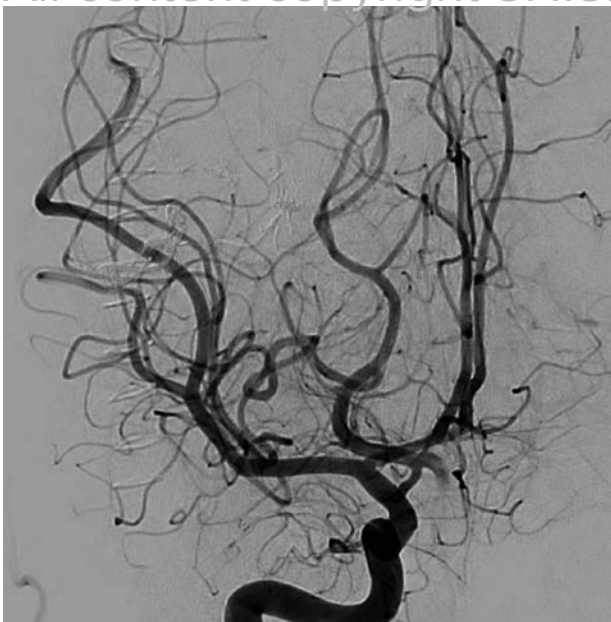


Figure 3. Angiogram of the same patient after surgical removal of the AVM.

Radiosurgery: involves a single treatment of highly focused radiation dose to obliterate the AVM. Radiosurgery is performed by a team consisting of a neurosurgeon and radiation oncologist. Unlike traditional surgery, the effect of radiosurgery is not immediate; once administered, the radiation destroys the AVM over a couple of years. While not always effective, radiosurgery has high cure rates for smaller AVMs, and is often the treatment of choice for AVMs in locations where traditional surgery would be very risky. There is a small risk of bleeding in the brain (usually delayed), and there is a very small chance of delayed development of malignant tumors.

Endovascular therapy: this is a minimally invasive procedure where catheters are placed into the arteries, usually through the leg artery in the groin or artery in the wrist, and it is used to seal off the AVM with glue or a glue-like substance (“embolization”). In some cases, endovascular therapy alone can “cure” the AVM, but most AVMs cannot be cured this way. Most often endovascular therapy is used prior to radiosurgery or surgical removal of the AVM to make those treatments safer and/or more effective. The main risk of endovascular therapy is causing a stroke or bleeding in the brain (Figure 4).

Often multiple treatment options are combined, especially for difficult, large and complex AVMs. Selecting the appropriate treatment is critically important to give each patient the best possible prognosis. Patients are advised to seek treatment at centers that are very experienced with all of the above AVM treatment options which optimizes the odds for the best patient outcome.

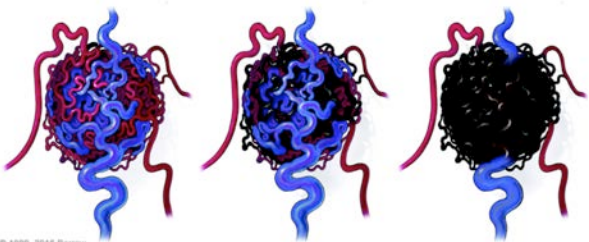


Figure 4. Illustration showing an AVM before and after endovascular embolization with Onyx in the vessels feeding the AVM.

Safety and Complications

Surgical risks and outcomes depend on AVM location, size and pattern of veins draining the AVM. The Spetzler-Martin grading scale combines these three factors and is used by surgeons to evaluate the surgical risks of resecting a given AVM.

The best method of treating an AVM should be determined on an individual basis. Immediately after a brain hemorrhage (bleed), the treatment may be to simply remove the blood clot and leave the AVM for treatment in a delayed fashion. In some patients after a large hemorrhage, the AVM and the blood clot may be removed at the same time. For unruptured AVMs, a detailed discussion of the risks and benefits of various treatment options, including conservative management, should be conducted with the patient and family.

There are inherent risks with either conservative or interventional treatment options. Data suggests a 1-3% per year risk of hemorrhage from an AVM. Given that most AVMs are identified in the 3rd or 4th decade of life, and the fact that AVM hemorrhage is associated with a 10-20% risk of death or serious disability, some patients may elect to undergo treatment for their AVM.

Which Procedure Should I Have?

The treatment of choice for an AVM, like all medical decisions, should be carefully discussed and decided upon by both the physician and the patient. In the case of both ruptured and unruptured AVMs, the treating physician should discuss the risks and benefits of the four treatment options listed above. The physician will usually make recommendations for one treatment over another, depending on the facts of each individual patient.

A Note on “A Randomized Trial of Unruptured Brain Arteriovenous Malformations” (ARUBA trial)

The NIH-funded ARUBA study was designed to guide the decision on whether to choose conservative or interventional treatment options for patients with unruptured brain AVMs. This question was challenging to study in a broad spectrum of AVMs with a variety of Spetzler-Martin grading risk features. The results of this study advocated for a more conservative approach in general to unruptured AVMs in the short-term. However, the management implications have been widely debated since the natural history of AVM rupture in the medically treated arm was not negligible (>3% rupture risk per year) and a longer term study follow-up is pending. Patients with unruptured AVMs would likely benefit most from discussing their management options with an experienced team that can provide all the treatment options.

©All content copyright SNIS.

Glossary of Terms

AVM: An abnormal tangle of blood vessels.

Angiogram: A radiographic study in which dye is injected in the arteries of brain. This is done through a catheter passed from an artery in the upper part of the leg or wrist. It reveals relevant anatomic details of the AVM.

Angiography: Radiography of blood vessels using the injection of material opaque to X-rays (contrast) to visualize vessels.

Catheter: A tube through which dye is injected in the arteries of the head and neck in order to reveal the AVM. Smaller catheters are often navigated directly into the vessels of the AVM and are used to inject embolic materials such as Onyx and nBCA.

Cerebrovascular: Pertaining to the blood vessels supplying the brain.

Craniotomy: A surgical procedure where a section of the skull cap is temporarily removed. This is necessary in the surgical treatment of AVMs.

Endovascular: Within the vascular system.

Endovascular Embolization: A technique that seals off the arterial or venous components of an AVM. This method uses natural access through the bloodstream via arteries and/or veins to occlude AVMs.

Hemorrhagic Stroke: A stroke caused by a ruptured blood vessel and characterized by bleeding within or surrounding the brain. Rupture of an AVM can lead to hemorrhagic stroke.

Minimally-Invasive Medical Technologies: Alternatives to traditional surgery that can, in select patients, reduce risk, trauma, cost, procedure time and time for recovery.

©All content copyright SNIS.

Founded in 1992 as the American Society of Interventional and Therapeutic Neuro-radiology (ASITN), the Society of Neuro-Interventional Surgery (SNIS) is a scientific and educational association with over 1,500 members worldwide. The SNIS is dedicated to advancing the specialty of neurointerventional surgery in order to provide the highest quality of patient care to the public. SNIS draws its membership from three areas – interventional neuro-radiology, endovascular neurosurgery and interventional neurology. It's the bringing together of these three subspecialties under one umbrella that gives SNIS its diversity and strength.

More information about SNIS is available at www.snisonline.org.

Email: info@snisonline.org

©All content copyright SNIS. All rights reserved.

Images used with permission from Barrow Neurological Institute, Phoenix, AZ

